

**THE PARASITIC STAGES OF *ISOSPORA LACAZEI*
LABBÉ (PROTOZOA:COCCIDIA) IN THE ENGLISH SPARROW**

等孢球蟲(原生動物門：球蟲目)在麻雀體內的發育時期

Yanung Chu Wang

諸 亞 儂

中 文 摘 要

本研究係由南伊利諾大學寄生蟲學教授 Dr. George Garoian, 鳥類學教授 Dr. Harvey I. Fisher, 組織學教授 Dr. Hermann Haas, 以及微生物學教授 Dr. Dan McClary 共同指導, 研究等孢球蟲 (*Isospora lacazei*) 在麻雀體內的發育時期。

等孢球蟲 (*Isospora lacazei*) 爲寄生的原生動物, 寄生於燕雀類及其他鳥類體內, 常使寄主發生球蟲病(coccidiosis)。過去文獻記載其形態, 彼此間常有差異, 此等報告, 係根據其隨寄主糞便排出之囊孢(oocyst)時期, 至於其在寄主體內的發育時期, 則研究者甚少, 但寄生蟲的生活史, 在寄生蟲學上頗爲重要, 故本研究乃以麻雀 (*Passer domesticus*) 爲材料, 鑑定等孢球蟲在麻雀體內寄生的部位及各發育時期的形態。結果與文獻記載本種球蟲在其他種類的寄主體內頗有差異, 這種差異究因受寄主影響或係不同種類的等孢球蟲, 則未敢定論。

等孢球蟲 (*Isospora lacazei*) 寄生於麻雀 (*Passer domesticus*) 小腸上部的上皮細胞內, 通常一上皮細胞內有一個寄生蟲, 在寄主細胞內行無性生殖和有性生殖; 行無性生殖的個體叫裂殖體 (schizont), 其細胞核分裂, 產生四個至八個分生子 (merozoite), 各分生子又可侵入另一上皮細胞, 再發育爲裂殖體, 產生分生子, 如是數代, 至最末代之分生子在寄主細胞內則形成有性生殖的配子母細胞; 雄配子母細胞 (microga-

metocytes) 的細胞核分裂，產生數以百計的雄配子 (microgamete)，雄配子呈半月形，含大量去氧核糖核酸 (DNA)，無鞭毛；雌配子母細胞 (macrogametocyte) 的細胞質內有很多顆粒 (haematoxylinophilic granule)，受精後，合子 (zygote) 內的顆粒乃漸漸消失，在合子表面產生一層薄壁，形成囊孢 (oocyst)，囊孢漸漸增大，遂破上皮細胞而出，至腸腔內，終隨寄主糞便排至外界。

ABSTRACT

The developmental stages of *Isospora lacazei* Labbé in the English sparrow (*Passer domesticus*) were investigated. This coccidium was found to be parasitizing only in the epithelial cell of the upper portion of the small intestine. The macrogametocytes considerably outnumber the microgametocytes, and the microgametocytes outnumber the schizonts. Schizonts, measuring averagely 11.7 by 10 microns in size, were found to contain 4 to 8 merozoites and occur at the distal portion of the host cells. Mature merozoites are crescentic in shape with an average size of 10.4 by 2.4 microns. Microgametocytes and macrogametocytes usually occur between the nucleus and the basement membrane in the host cells. The microgametocytes with a size of 12.04 by 8.9 microns contain numerous microgametes around the periphery. Sickle-shaped microgametes, with an average of 3.5 microns in length and 0.5 micron in width, are rich in DNA which however, is poor in the nucleus of merozoite and macrogametocyte. Macrogametocytes, measuring averagely 15.9 by 14.5 microns in size, possess a nucleus with a large centric endosome and cytoplasm containing large haematoxylinophilic granules. After fertilization, the endosome of the zygotes diminishes in size and the haematoxylinophilic granules contribute to the formation of the oocyst wall. The oocysts so-formed are then released after the host cells burst up, and passed out with the host feces ending the parasitic stages of development. The parasitic stages established in this study are considerably different from those reported by Hosoda and Wasielewski. These morphological differences are attributed most probably to the influences of different hosts.

INTRODUCTION

The coccidia are parasitic protozoa found in various vertebrates and some invertebrates. They usually cause a disease known as coccidiosis which is

sometimes severe in birds and mammals. According to Becker (1956) and Levine (1963), a total of 532 coccidian species in 12 genera are known. Among them, 237 species have been found in mammals and 108 in birds. *Isospora* is one of the coccidian genera with a total of 87 species having been reported. *Isospora lacazei* Labbé was first described by Labbé (1895) under the name of *Diplospora lacazii* from the European goldfinch (*Cardulus cardulus*), European skylark (*Alauda domesticus*), and other unnamed birds in France. Labbé (1896) later reported its occurrences in the English sparrow (*Passer domesticus*) and other birds, and emended the species name as *lacazei* in honour of Felix Joseph Henri de Lacazei Duthiers (1821-1901). As early in 1881, *Isospora* had already been erected by Schneider as the generic name for a coccidian species from the black slug with similar oocysts, the generic name *Diplospora* coined by Labbé was accordingly changed to *Isospora* following its priority.

Although this coccidium has been reported from a large number of passeriform and other birds (Boughton, 1938; Sholtyssek, 1954, 1956; Rasavy, 1954, 1956), almost all the published reports were, however, mainly based on the morphological studies of the oocysts, their descriptions and illustrations are often not alike and even sometimes contradictory, therefore whether all the forms reported under this same name actually belong to the same species remains to be determined. Besides, the oocysts in the coccidian life cycle are most easily collected and cultured, they have been generally more thoroughly investigated while the parasitic stages in the host were relatively neglected. Since the experimental work in parasitology, as in many other fields of biological endeavors, can be accomplished effectively only after the complete life histories of the organisms involved have been established, no study on *Isospora lacazei* will be reliable and considered complete without going into the endogenous phases of its life cycle.

Wasielewski (1904) was considered the one for the first time delineated the life history of *Isospora lacazei* from the wild bird in Germany, and Hosoda (1928), the first to describe *Isospora* from the passeriform birds, *Passer montanus saturatus*. Hosoda's figures were later reproduced by Becker (1934) and have been considered as standard for *Isospora lacazei* ever since. As life history of this coccidium from *Passer domesticus* has not yet been worked out, and as the comparative studies of the morphology of parasitic stages of *Isospora lacazei*

in different hosts are important, therefore the present investigation is undertaken.

MATERIALS AND METHODS

The English sparrows (*Passer domesticus*) were caught at the campus of Southern Illinois University from June through August, 1964, with a bird trap designed by Dr. Harvey I. Fisher, Chairman of the Department of Zoology. Altogether 18 sparrows were obtained and kept in suitable cages for the present investigation. Since Boughton (1933) has reported the discovery of a remarkable diurnal periodicity in oocysts elimination in the afternoon by the English sparrow and other passerine birds, the fecal samples of the sparrow were constantly collected and examined during that time. Whenever coccidian oocysts were found to present in the fecal samples, the naturally infected birds were killed by etherbreathing. Then the whole length of the intestine, the pancreas, liver, and the gallbladder were closely examined, and pieces of these organs were fixed in either Carnoy's fluid or Bouin's solution. These fixed pieces were then impregnated with paraffin wax (M. P. 54°C), sectioned to 5 to 6 microns thick, and stained. During the processes, the haematoxylin and eosin counterstain method was found to be satisfactory; the Feulgen nuclear reagent was used to test for the DNA presented in the nucleus of the parasites according to Humanston (1962); and the smear of gut contents were fixed with Carnoy's fluid and stained with Giemsa. The whole procedure was repeated with each sparrow found naturally infected, and in this way, a total of 300 serial slides were made. These serial slides were examined under microscope with magnification from 100 to 1,000 times, and each stage of the endogenic development so found was photographed (Figs. 1-14) and also drawn with the aid of camera lucida (Figs. 15-29). These stages are described as the following section.

RESULTS

Effects on the host

Among the 18 sparrows investigated, 15 of them were found to be naturally infected with *Isospora lacazei*. The infected sparrows show no outward signs of infection. Their feces were well formed in appearance, although coccidian oocysts were found in the feces.

Examination of the feces shows that the elimination of the oocysts reaches a peak high between 3 to 8 o'clock in the afternoon daily but is much less in

number during the time preceeding and subsequent to the peak hours. In the morning it is negative. Despite careful examination, none of these organs reveals any signs of disease.

Structure of the parasitic stages

The life history of *Isospora lacazei* from the English sparrow is quite typical for the genus. After a series of multiplication of the schizont, the sexual gametes appear. During this stage of its life cycle, the microgametes fertilize the macrogametocytes resulting in the formation of zygotes which later form oocysts and are released into the lumen of the intestine after the host epithelial cells burst up. The various stages during the endogenous development are described as the following:

1. Locale of infection. All the parasitic stages occur in the upper portion of the small intestine (Fig. 1), and have never been found in its lower portion, caecum, rectum, and other organs. The parasite, usually one in one host cell, becomes oval and enlarges after its entering in the intestinal epithelium (Figs. 14 and 15). As the parasite grows, the host cell swells at the portion where the parasite is located. After the host cell bursts up, the parasite is then released.

The macrogametocytes considerably outnumber the microgametocytes, and the microgametocytes outnumber the schizonts. In the present investigation, only a few of the schizonts were observed.

2. Schizonts and schizogony. The schizonts were always found at the distal portion of the epithelial cells. The mature schizonts are round and oval-shaped with an average size of 11.7 by 10.0 microns. Their nuclei are divided producing 4 (Figs. 2 and 16) to 8 (Figs. 3 and 17) premerozoites which later elongate forming slender merozoites (Figs. 4 and 18). The mature merozoites are crescentic or banana in shape, with a size of about 10.4 microns in length and 2.4 microns in maximum width, and an oval nucleus in the central portion (Figs. 5 and 19).

3. Microgametocytes. The microgametocytes are formed from merozoites. After a merozoite enters an epithelial cell, it rounds up; but whether it will develop into a macrogametocyte, a microgametocyte, or a schizont depends completely on the conditions of its nuclear division. In case the nucleus of the merozoite is divided into many nuclei, it apparently is developing into a microgametocyte or a schizont; but in case the nucleus remains undivided, a

macrogametocyte is expected to be formed. The nuclei of the schizonts and microgametocytes can be distinguished from their morphology. Generally speaking, the nuclei of the schizont are larger in size and less in number while these of the microgametocytes are smaller and more numerous. The microgametocytes as well as the macrogametocytes are located at the basal portion of the host cells.

The microgametocytes as observed in the present investigation appear generally as large cells containing many dark oblong nuclei near the surface (Figs. 6, 20 and 21). As development continuously goes on, the microgametocytes grow in size, and the nuclei elongate and thicken until at long last each of them becomes a microgamete (Figs. 7, 22 and 23). The mature microgametocyte has an average size of 12.04 microns in length and 8.9 microns in width while the mature microgamete with an average of 3.5 microns in length and 0.5 micron in width. The mature microgametes are sickle in shape; but whether flagella are present as reported by Hosoda, it was impossible to confirm during the present investigation.

The microgametocytes are the only stage positive to Feulgen nuclear reagent. According to this test, it was found that the microgametes contain large amount of DNA (Figs. 8, 9, 10, 24, 25 and 26).

4. Macrogametocytes. The macrogametocyte is a spherical cell containing a relatively large homogeneous nucleus with an endosome. Its cytoplasm contains many large haematoxyphilic granules (Figs. 11, 12 and 27). The macrogametocyte increases in size during its development; the mature macrogametocyte were measured with an average size of 15.9 by 14.5 microns. The nucleus is ellipsoidal with an average size of 5.6 by 4.7 microns and containing a large centric endosome. Actual fertilization of the macrogametocyte with a microgamete was not observed.

5. Zygotes. The zygotes (Figs. 13 and 28) developed from fertilized macrogametocyte have a nucleus less distinct and an endosome in much diminished size. Meanwhile the haematoxyphilic granules disappear, then the cytoplasm becomes spongy and appears less intensely stained. All these features serve well for distinguishing them from the unfertilized macrogametocyte. The zygote produces later a thin wall forming an oocyst (Figs. 14 and 29), and the developing oocyst increases further in size and is released into the gut lumen after the epithelial cell bursts up. These oocysts are finally passed out of the host body

with the feces and sporulate outside producing infectious sporozoites.

DISLUSSION

The following is a discussion of the parasitic stages of *Isospora lacazei* Labbé in *Passer domesticus* found in this study as compared to those from other hosts reported by Hosoda and Wasielewski. These morphological comparisons have been compiled together in Table I.

As reported above, *Isospora lacazei* develops primarily in the epithelial cell of the upper portion of the small intestine of *Passer domesticus*. But in Hosoda's work, this same coccidium was reported to occur not only throughout the entire length of the small intestine, but also in the caecum and rectum of *Passer montanus*.

In all three cases, schizont was found to occur exclusively in the distal portion of epithelium; but the merozoite produced within the schizont appears to be different in different hosts. In Hosoda's report, no mention was made on the number of merozoites within the schizont while Wasielewski gave a number of 8 to 12. In the present investigation, the number of merozoites was found to be 4 to 8. As to the size of merozoite, Hosoda had mentioned of three different sizes; but in the present investigation, only one size was observed, and this size as measured in the smear preparation averages 10.4 by 2.4 microns, similar to the largest form reported by Hosoda.

The macrogametocytes are generally bigger than the microgametocytes; nevertheless, according to Wasielewski, the latter measured to be 28 by 21 microns in size, and much larger than the macrogametocytes reported by the present author and Hosoda. According to Hosoda the cytoplasm of the macrogametocyte contains both haematoxynophilic granules and plastic granules but in the present investigation, only haematoxynophilic granules were observed. It seems that the plastic granules are not likely to be present in the macrogametocyte of *Isospora lacazei* in *Passer domesticus*. Besides, the microgamete reported by Hosoda possesses two fine flagella one at each end which, however, were not observed in the present study and Wasielewski's investigation.

From the above discussion, it is evident that the parasitic stages of *Isospora lacazei* appear different in different hosts. Whether these differences signify a new species of *Isospora* or merely a result of the influences of different hosts, data are not enough to warrant a confirmative judgement.

Table I. Comparison of parasitic stages of *Isospora lacazei* from various hosts (Measurements in Microns)

	<i>Passer domesticus</i>	<i>Passer montanus saturatus</i>	Wild bird
Locale of infection	Epithelial cell of upper portion of small intestine.	Epithelial cell of small intestine, caecum, rectum.	Epithelial cell and mucous gland of small intestine.
Location of schizont	Distal portion of host cell.	same	same
Location of microgametocyte and macrogametocyte.	Basal portion of host cell.	same	same
Number of merozoites within schizont	4 to 8	not stated	8-12
Size of merozoite	8.8-11 by 2.4	3 sizes: 7.0-8.2 by 1.5-2 5.0-6.5 by 1.2-1.5 8.5-9.5 by 2.0-2.4	8-12 by 2-3
Size of microgametocyte	12.04 by 8.9	not stated	28 by 21
Size of microgamete	2.4 to 4 long with an average of 3.5	2.5-3	2-4
Flagellum of microgamete	not observed	2 flagella, one at each end.	not observed
Plastic & haematophyllous granules.	plastic granules not observed.	both are present	not stated
Size of macrogametocyte	15.92 by 14.5	13.0-18.5 by 9.0-16.0	not stated

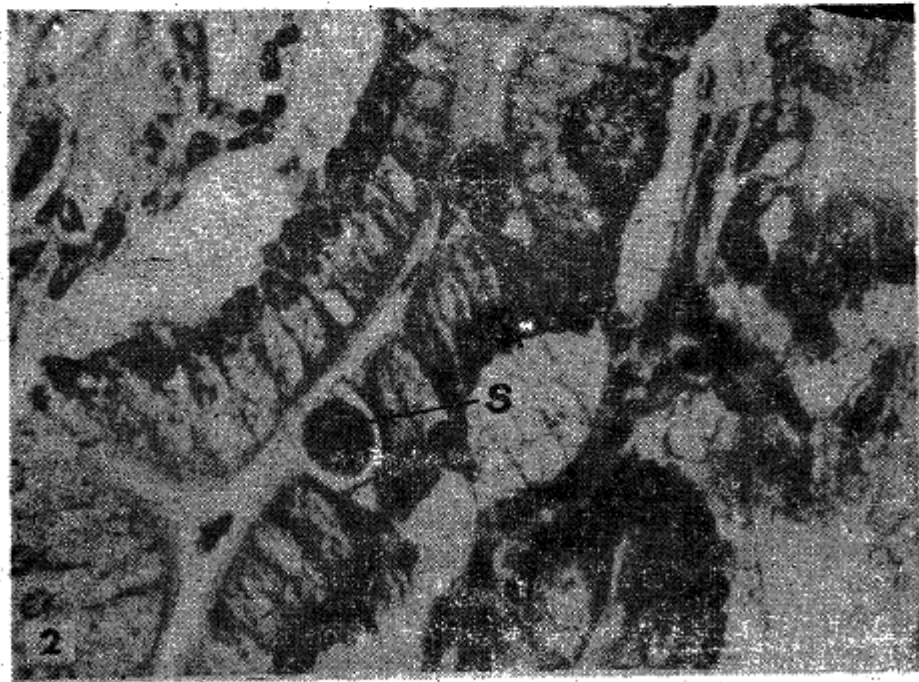
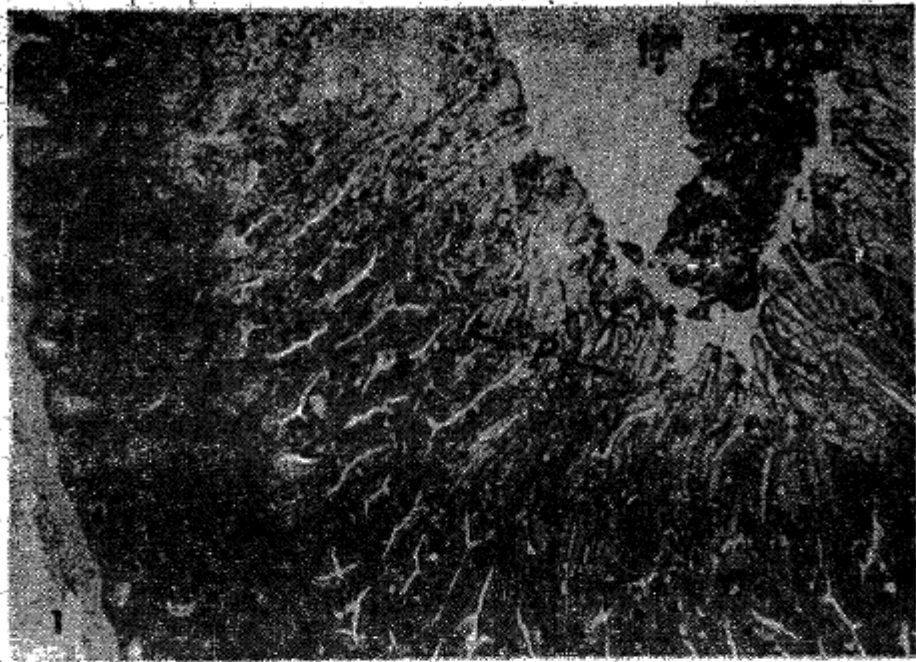
ACKNOWLEDGEMENTS

The present contribution is prepared as part of the fulfillment for the Master Degree in zoology in the Department of zoology, Southern Illinois University. Dr. George Garoian, advisor to the author for her Master program, planned and directed this work with most thoughtful guidance; to whom the writer's most sincere thanks are due. During the course of research, Dr. Harvey I. Fisher advised the writer on the matter concerning the host birds, Dr. Hermann Haas helped in the preparation of slides, to these gentlemen, the writer is most grateful of their most instructive assistance, The writer is also indebted to Dr. John M. Fong, Medical College, National Taiwan University, for the most clear photographs accompanied as illustrations in this paper and to Dr. Shu Yeh of the same institute for his kindness in giving her the privilege for free use of the photograph facilities set up in his research laboratory.

LITERATURES CITED

- Becker, E. R. 1943. Coccidia and coccidiosis of domesticated game and laboratory animals and of man. pp.99-101, Ames, Iowa: Iowa State College.
- _____. 1956. Catalog of Emeridae in genera occurring in vertebrates and not requiring intermediate hosts. Iowa State Coll. Jour. Sci., 31: 85-139.
- Boughton, D.C. 1933. Diurnal periodicity in the oocyst-production of the sparrow *Isospora*. Jour. parasit., 19: 177.
- Hosoda, S. 1929. Studien über die Entwicklung und Vermehrung der *Isospora lacazei* Labbé. Fukuoka. Ikwabaigaku zasshi, 21: 885-930.
- Humanson, G. L. 1962. Animal tissue techniques, pp. 51-70, San Francisco and London: Freeman.
- Labbé, A. 1893. Sur les Coccidies des Oiseaux. Compt. Rend. Acad. Sci., paris 116: 1300-1303.
- Labbé, A. 1896. Recherches zoologiques, Cytologiques et biologiques sur les coccidies. Arch. zool. Exper., Gen 24 (3 ser., v., 4): 517-654.
- Levine, N. D. 1963. Coccidiosis, Ann. Rev. Micro., 17: 179-196.
- Levine, N. D., and Mohan, R. N. 1960. *Isospora* sp. (protozoa: Eimeriidae) from cattle and its relationship to *Isospora lacazei* of the English sparrow. Jour. parasit., 46: 733-741.

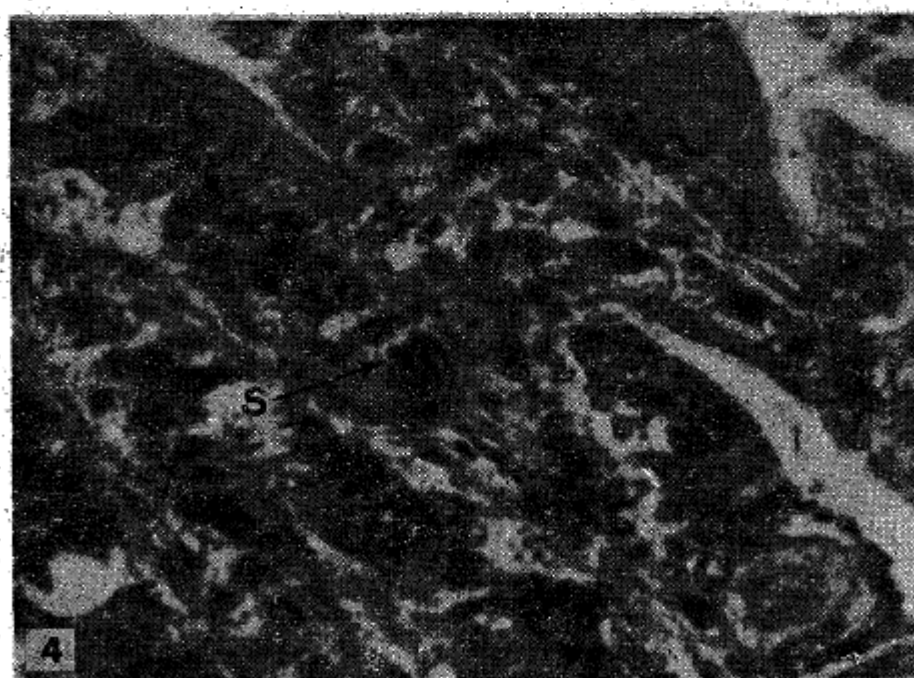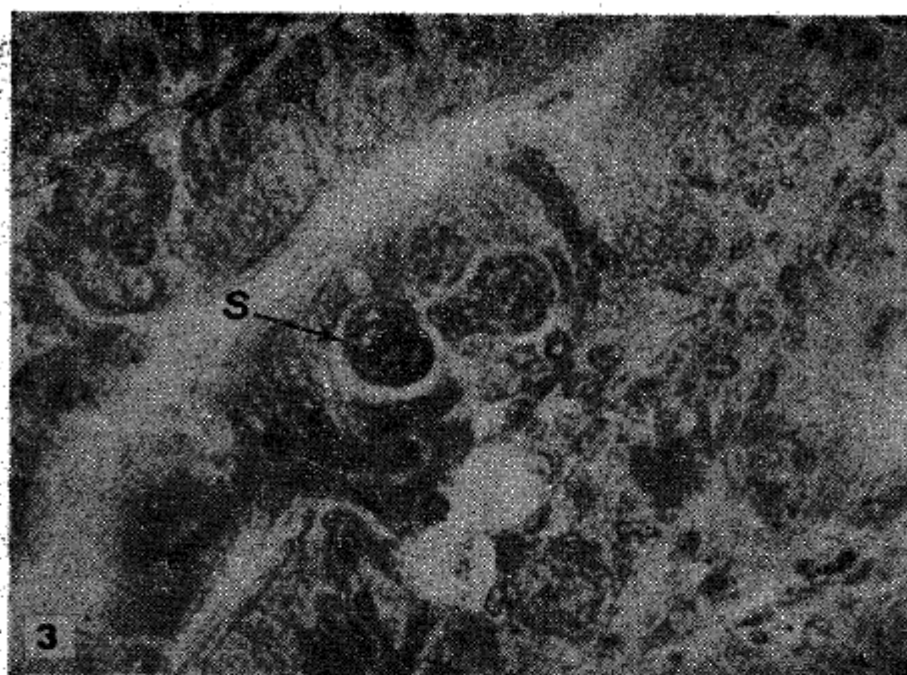- Rasavy, B. 1954. Príspevek k posnani kokeidii i dovezenych obratlovcu, Cesk. Parasit., 1:137-174.
- _____. 1956. Die Frage der Spezifizität und Variabilität der Coccidien bei verschiedenen Wirten. Folia. Biol., 2: 67-71.
- Schaltyssek, E. 1954. Untersuchungen über die bei einheimischen Vogelarten vorkommenden Coccidien der Gattung *Isospora*. Arch. Prot., 100: 91-112.
- _____. 1956. Untersuchungen über die Coccidieninfektion bei Vögeln. Zbl. Bpt. I, Abt. Orig., 165: 275-289.
- Wasielowski, T. von. 1904. Studien und Mikrophotogramme zur Kenntnis der pathogenen Protozoen I Heft III Über den Erreger einer Coccidienseuche bei Vögeln (*Diplospora lacazei*). pp. 69-98, Leipzig.



Figures 1-2. photomicrographs of the parasitic stages of *Isospora lacazei* Labbé in the English sparrow.

1. Cross section of the upper portion of the small intestine showing the locale of infection with the parasites (p) in epithelial cells. 150x.

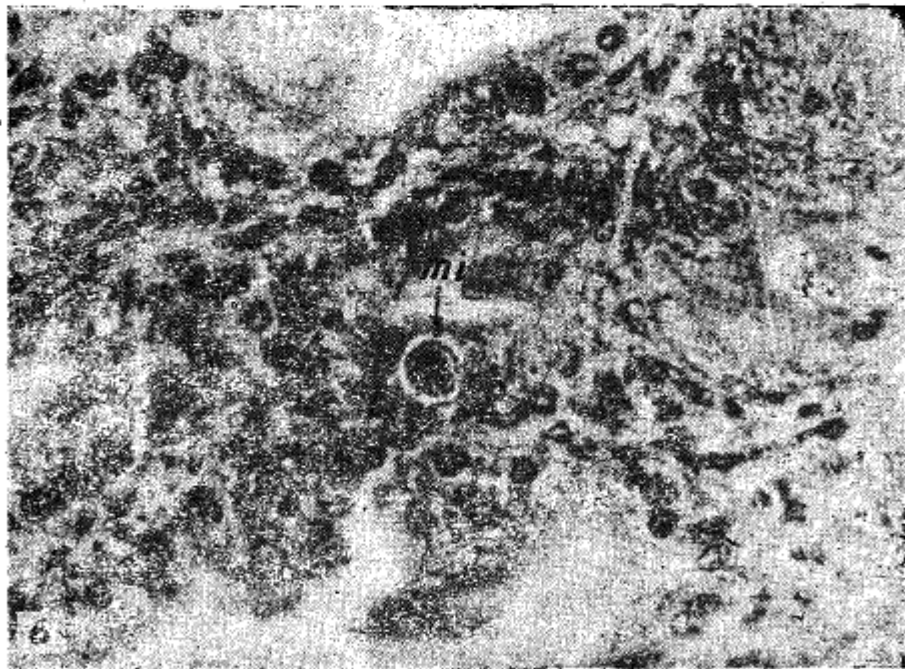
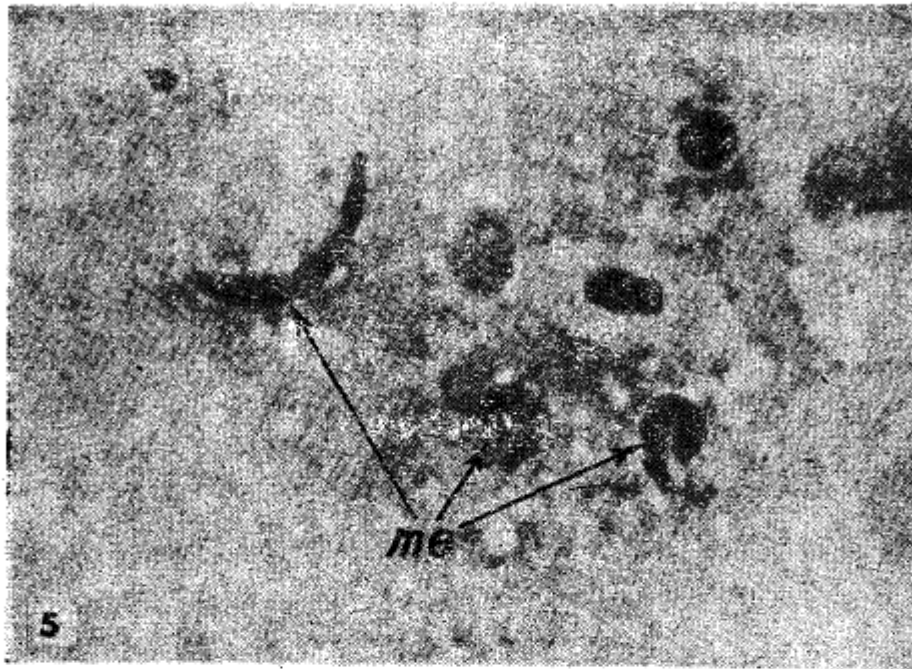
2. Schizont (s) containing 4 premerozoites. 800x.



Figures 3-4. photomicrographs of the parasitic stages of *Isospora laevis* Labbé in the English sparrow.

3. Schizont (s) containing 8 premerozoites. 800x.

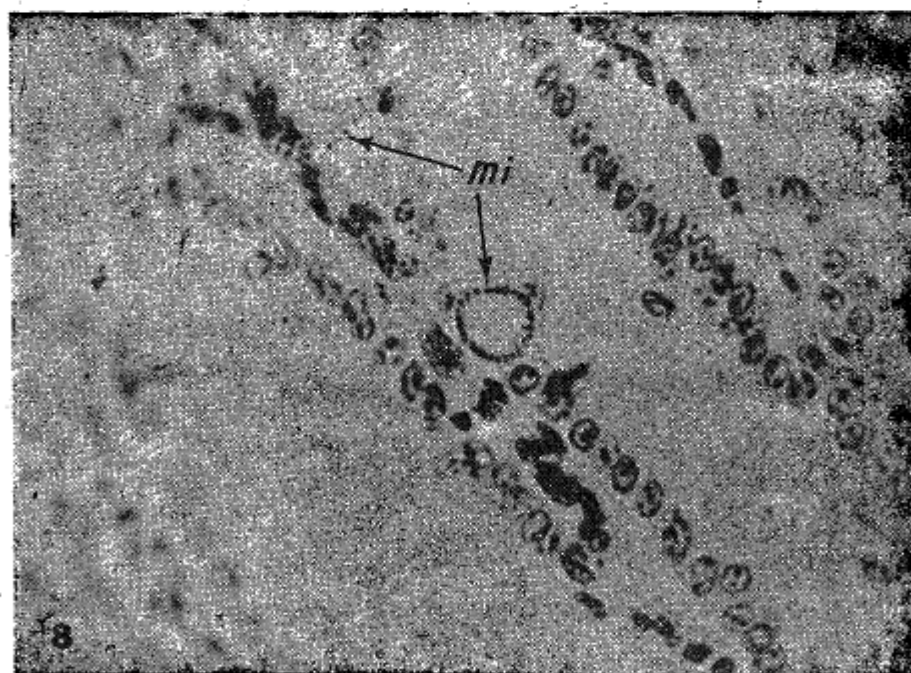
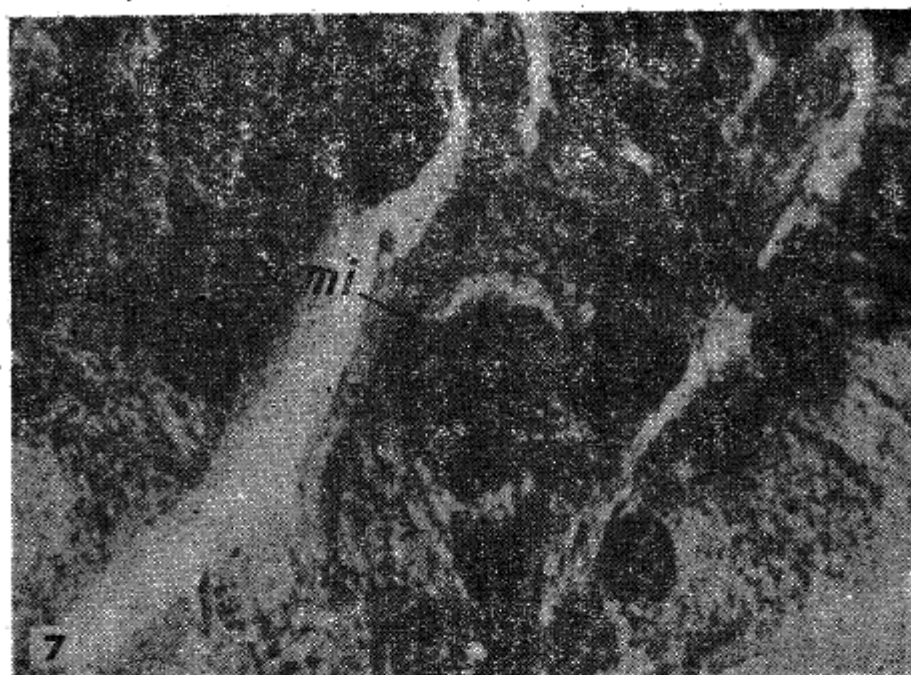
4. Schizont (s) with merozoites. 800x.



Figures 5-6. Photomicrographs of the parasitic stages of *Isospora lacazei* Labbé in the English sparrow.

5. Mature merozoites (me) in the gut contents, 1600x.


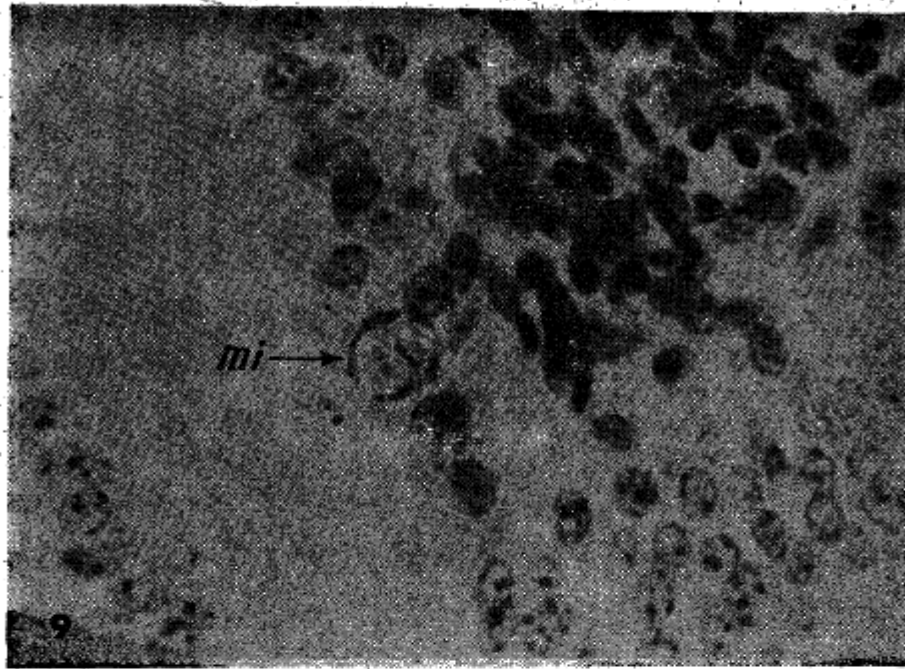
6. Microgametocyte (mi) containing nucleated pregametes. 800x.



Figures 7-8. Photomicrographs of the parasitic stages of *Isospora lacazei* Labbé in the English sparrow.

7. Mature microgametes inside the microgametocyte (mi). 1600x.

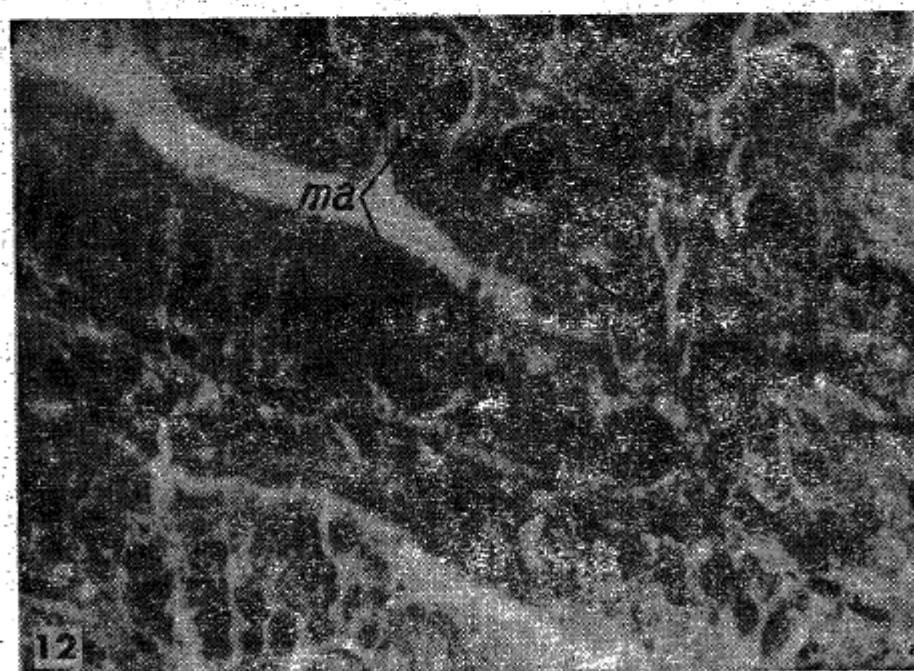
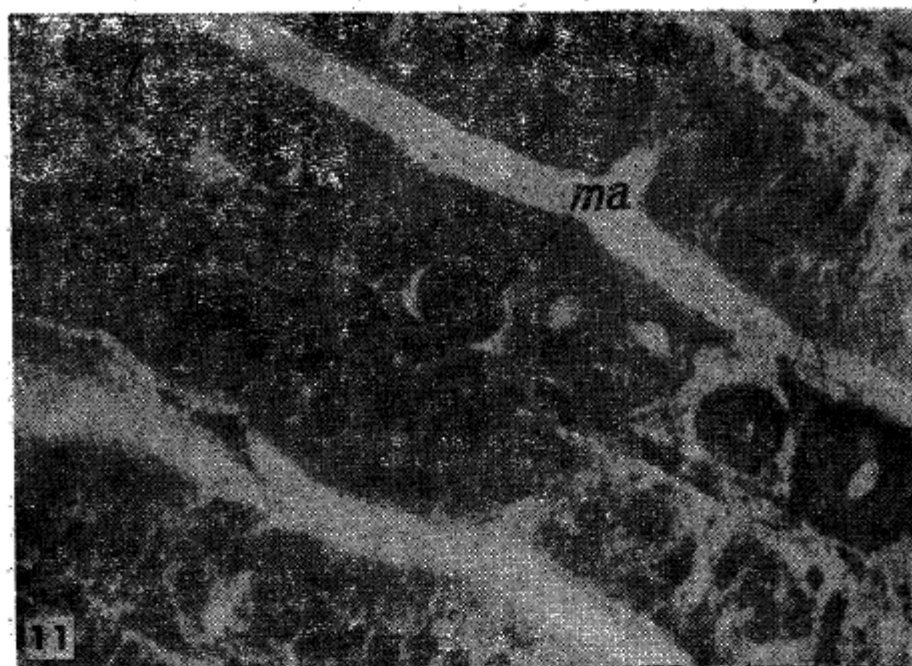8. Microgametocytes (mi) containing nucleated pregametes positive to Feulgen nuclear reagent. 800x.



Figures 9-10. photomicrographs of the parasitic stages of *Isospora lacazei* Labbé in the English sparrow.

9. Microgametocyte (mi) with mature microgametes positive to Feulgen nuclear reagent 800x.

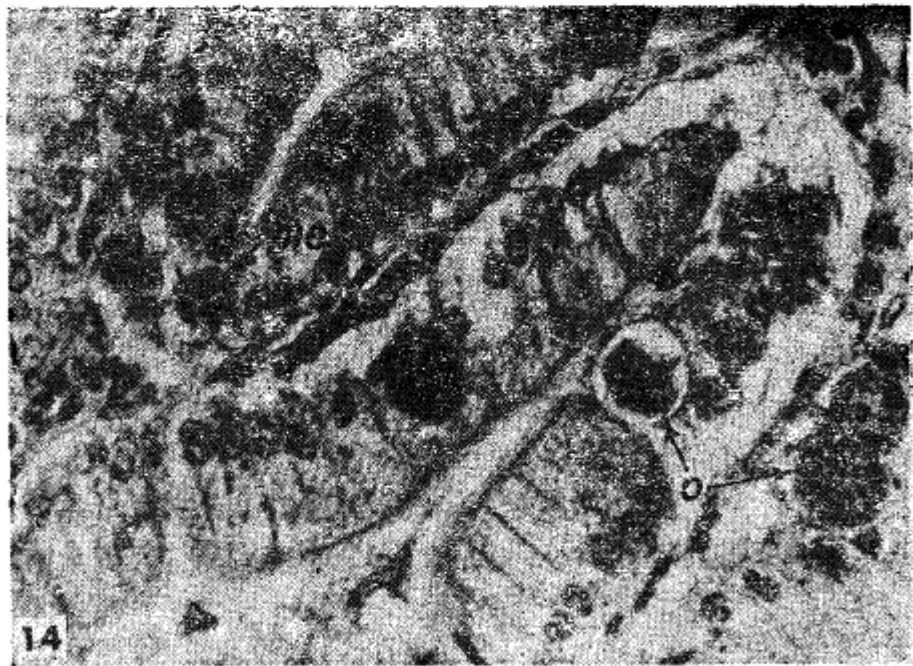
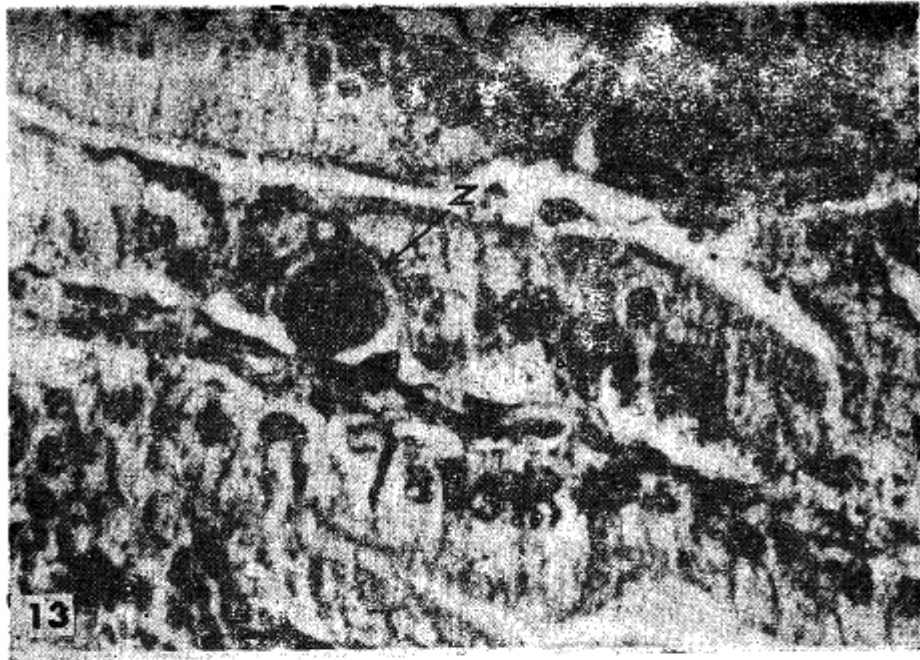
10. Microgametocyte (mi) with mature microgametes positive to Feulgen nuclear reagent. 1600x.



Figures 11-12. photomicrographs of the parasitic stages of *Isospora* Labbé in the English sparrow.

11. A nearly mature macrogametocyte (ma). 800x.

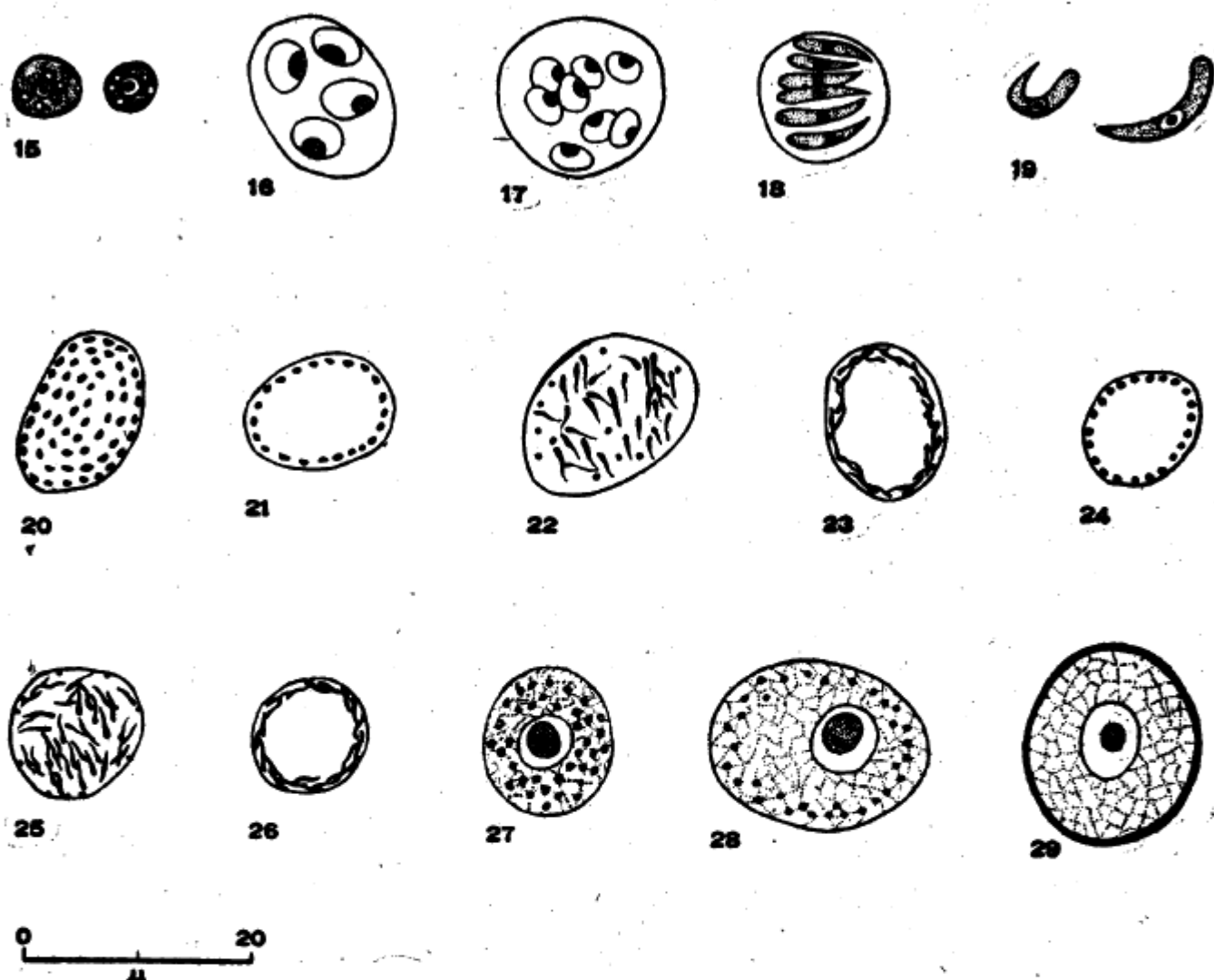
12. Mature macrogametocytes (ma). 800x.



Figures 13-14. photomicrographs of the parasitic stages of *Isospora lacazei* Labbé in the English sparrow.

13. zygote (z) with diminished endosome. 800x.

14. Rounded up merozoites (me) in the epithelial cells. Oocysts (o). The left one is releasing from the epithelial cell. 800x.



Figures 15-29. Line drawings of the parasitic stages of *Isospora lacazei* in the English sparrow. 15. Early stage of parasite in host cell. 16. Schizont containing 4 premerozoites. 17. Schizont containing 8 premerozoites. 18. Schizont with merozoites. 19. Mature merozoites. 20. Microgametocyte containing nucleated pregametes. 21. Microgametocyte containing nucleated pregametes at the periphery. 22. Mature microgametes inside the microgametocyte. 23. Mature microgametes inside the microgametocyte at the periphery. 24. Microgametocyte containing nucleated pregametes positive to Feulgen nuclear reagent. 25. Microgametocyte containing mature microgametes positive to Feulgen nuclear reagent. 26. Microgametes positive to Feulgen nuclear reagent at the periphery of the microgametocyte. 27. A mature macrogametocyte. 28. A zygote. 29. A newly formed oocyst.